

Case study:

Basal cell carcinoma, right forehead and scalp

*Contributed by Ally-Khan Somani, MD, PhD, EMBA, FAAD, FACMS, FASDS, FEADV, FESMS
Director of Dermatologic Surgery & Cutaneous Oncology Division
Assistant Professor, Department of Dermatology
Adjunct Assistant Professor of Otolaryngology-Head and Neck Surgery
Indiana University School of Medicine, Indianapolis, Indiana, US*

OASIS[®]
EXTRACELLULAR MATRIX



Case study: basal cell carcinoma, right forehead and scalp

Patient

52-year-old female

History

Basal cell carcinoma of right forehead and scalp

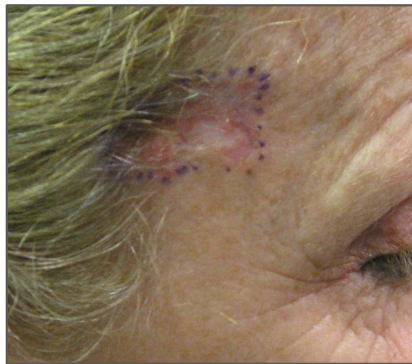
Details

Mohs stage: 3
Defect size: 4.2 x 5.3 cm
Depth: muscle

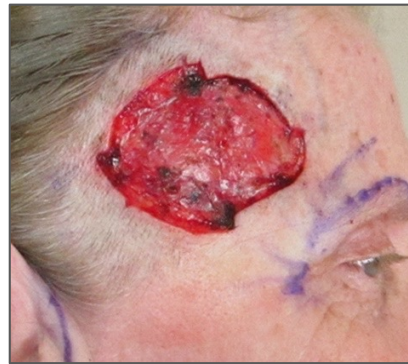

OASIS® EXTRACELLULAR MATRIX

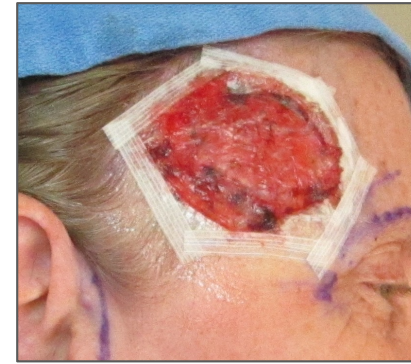Case study: basal cell carcinoma, right forehead and scalp



Day 0
Ulcerated nodular
basal cell carcinoma



Day 0
Defect after excision



Day 0
OASIS Wound Matrix applied
and affixed with Steri-Strips®

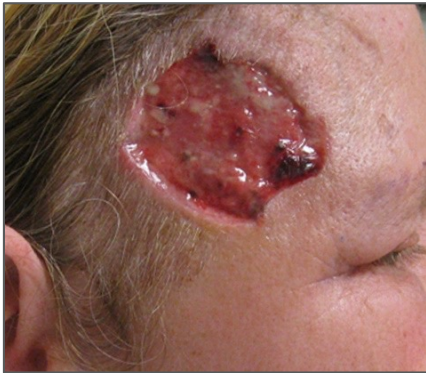

Note: Individual results will vary.
OASIS Wound Matrix is the product name in the US.
OASIS Extracellular Matrix is the product name outside the US.
Steri-Strip is a registered trademark of 3M.

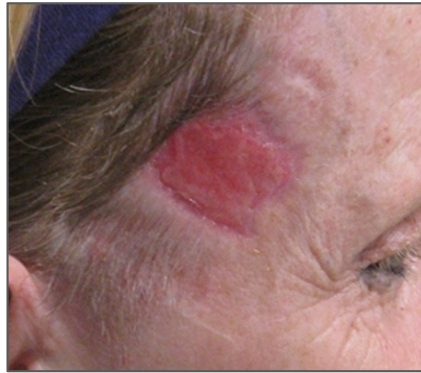COMPANY CONFIDENTIAL. DO NOT COPY. NOT FOR EXTERNAL DISTRIBUTION.

OASIS® EXTRACELLULAR MATRIX

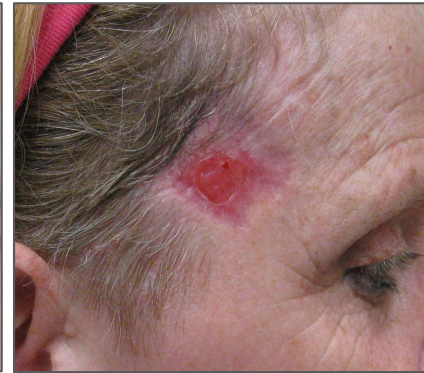Case study: basal cell carcinoma, right forehead and scalp



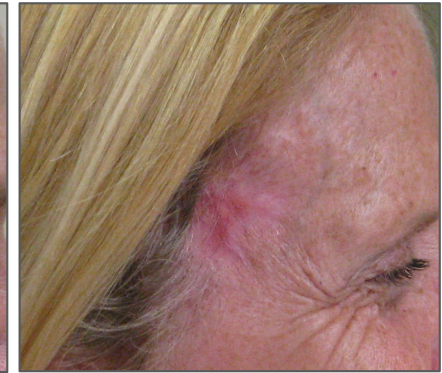1 week after OASIS Wound Matrix application
Wound decreased in size, with wound bed carmelisation



2 weeks after OASIS Wound Matrix application



6 weeks after OASIS Wound Matrix application



5 months after OASIS Wound Matrix application
Complete healing with minimal residual erythema



Note: Individual results will vary.
OASIS Wound Matrix is the product name in the US.
OASIS Extracellular Matrix is the product name outside the US.

COMPANY CONFIDENTIAL. DO NOT COPY. NOT FOR EXTERNAL DISTRIBUTION.