

Kendall™ AMD Antimicrobial Foam Dressings

made easy

Volume 3 | Issue 2 | May 2012 www.woundsinternational.com



Introduction

Kendall™ AMD antimicrobial foam dressings incorporate the effective antimicrobial agent **polyhexamethylene biguanide (PHMB)** with a highly absorbent foam. These dressings are particularly suited to the management of acute or chronic wounds with moderate to high levels of exudation where there is an increased risk or evidence of wound infection.

Authors: Spruce P, Edwards-Jones V, Ivins N, Sibbald RG, Shah C, Patel H. Full author details can be found on page 6.

Role of antimicrobial dressings

All chronic wounds contain a mixture of different bacteria, often from the patient's skin or intestinal tract. These may include some known pathogens that ultimately cause infection. Common pathogens seen in chronic wounds include *Staphylococcus aureus*, *Pseudomonas aeruginosa*, *Escherichia coli*, and occasionally a mixture of anaerobic bacteria and fungi. The bacteria may secrete a range of toxins and enzymes that degrade newly formed tissue and perpetuate an inflammatory reaction. This may cause problems such as delayed wound healing or wound degradation¹.

Furthermore, it is now widely accepted that most chronic wounds contain biofilms². These comprise a thin layer of microorganisms, which are bound in a matrix of secreted polymers that adhere to the wound bed surface³. Bacteria growing in a biofilm are up to 1,000 times more resistant to antibiotics than the same bacteria outside a biofilm⁴. As a result, systemic antimicrobial therapy may not be effective.

In recent years, the management of increased wound bioburden has moved towards the use of topical antimicrobial agents because of mounting recognition of the problems caused by antibiotic resistance. Unlike antibiotics, which generally have a single mode of action, topical antimicrobial agents tend to have multiple modes of action on microbial cells. This means that they have a broad spectrum of antimicrobial activity and a low risk of developing resistance⁵. Increasingly, topical antimicrobial agents are being incorporated into wound dressings.

One of the most promising ways of dealing with a biofilm is to debride the wound bed and then apply a topical antimicrobial agent. Debridement has been shown to reduce bacterial load by 10-100 fold (ie by 1–2 logarithms)⁶. After debridement there

is an opportunity to further disrupt the biofilm and prevent reformation through the use of topical antimicrobial agents to kill exposed bacteria⁷. Together these approaches may reduce bacterial burden sufficiently to allow wound healing to progress³.

Detecting wound infection

The early detection of wound infection depends on the skill of the clinician to recognise the signs and symptoms of increasing bacterial activity in the wound. In acute and chronic wounds, the diagnosis of infection should be based on signs and symptoms in and around the local wound bed, the deeper structures, and the surrounding skin. The first signs of critical colonisation or local infection may be delayed wound healing, a purulent discharge, red friable granulation tissue, new debris or dead cells on the surface of the wound and possible malodour⁸.

In chronic wounds, changes to the wound bed due to increasing bacterial burden may include discolouration, pocketing, bridging, and fragile or bleeding granulation tissue⁹. It has also been demonstrated that increased pain and wound breakdown are initial indicators of infection in most chronic wounds¹⁰. In some patients the classic signs of localised infection may be diminished, for example, patients with diabetes or individuals who are immunocompromised¹¹.

It is important that clinicians are able to distinguish between superficial bacterial damage (ie localised infection) and spreading or deep infection, which usually requires systemic antimicrobial treatment⁸.

Using topical antimicrobial dressings

Topical antimicrobial treatment should commence when the first signs and symptoms of localised wound infection are observed, and should be discontinued when these subside and the wound is consistently progressing towards healing. It is important that if the wound remains unchanged after 14 days of treatment, an alternative antimicrobial agent be considered. The antimicrobial dressing selected should be appropriate for the tissue type, amount of exudate and patient comfort. Systemic antibiotics should be considered only if there are signs of spreading or systemic infection⁹.

What are Kendall™ AMD antimicrobial foam dressings?

Kendall™ AMD antimicrobial foam dressings are made of polyurethane foam, which is impregnated with the antimicrobial agent PHMB and have been designed to facilitate moisture and bacterial management.

Kendall™ AMD Antimicrobial Foam Dressings made easy



The dressings are recommended for use on acute and chronic wounds that are moderately to heavily exuding, and where an increase in bioburden may cause a delay in healing¹².

They are available in a variety of sizes and specifications. As well as the standard double-sided foam dressings, some have a polyurethane backsheet to prevent strikethrough (Box 1). There is also an adhesive bordered version available. The fenestrated and disc versions may be used to promote a healthy environment around exit sites, such as percutaneous endoscopic gastrostomies (PEGs), suprapubic catheters and tracheostomy wounds. They also provide a protective barrier at catheter insertion sites such as central venous catheters (CVC) and peripherally inserted central catheters (PICCs)¹³.

Composition and exudate absorption

The foam of Kendall™ AMD antimicrobial foam dressings contains PHMB at a concentration of 0.5%. This may prevent the passage of microorganisms and cross-contamination from a patient to the surrounding environment and *vice versa*¹⁴.

The dressings are constructed to provide effective exudate handling, with a vertical wicking action, while maintaining a moist wound environment and delivering antimicrobial efficacy. The dressings do not shed fibres or particles, are conformable and easy to remove.

The wound contact surface of the foam is non-adherent and has an open-cell, 'honeycomb' structure that encourages rapid absorption of exudate vertically into the core of the dressing. The inner core of the foam has a larger honeycomb structure that facilitates the retention of exudate (Figure 1).

The dressing swells as it absorbs fluid, minimising pooling of exudate in the

wound bed and maceration of the surrounding skin. If the amount and flow of exudate decrease, the foam shrinks so that the rate of exudate uptake through the surface of the dressing is reduced to maintain optimal moisture balance and avoid excessive drying of the wound surface. Localised swelling of the dressing helps to reduce and seal any space that may exist between the dressing and the wound.

Any bacteria contained within the exudate and absorbed by the dressing are exposed to the antimicrobial action of PHMB.

How does PHMB work?

PHMB has been used for a number of years as an antiseptic agent in baby wipes, for decontaminating brewery equipment, and as the antiseptic solution for contact lenses. It has more recently been used in gauze and foam dressings, and as a solution, for the treatment of wounds. PHMB works by:

- **binding to the bacteria cell's outer membrane**
- **inhibiting bacterial cell metabolism**
- **inducing cell lysis and death.**

PHMB is a positively charged molecule that attaches to the negatively charged

phospholipids in the cell membrane of bacteria. This disrupts the integrity of the cell membrane and the cell is no longer able to control normal transmembrane ion exchange. Ultimately, holes develop in the cell membrane and the cell leaks, causing it to collapse and die^{15,16}.

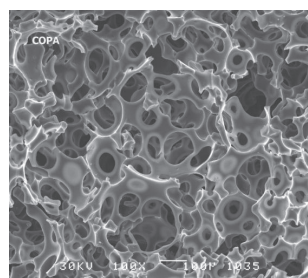
In addition, PHMB disrupts bacterial cell metabolism¹⁶. These multiple modes of action make it highly unlikely for microorganisms to develop resistance to PHMB. Indeed, it has been used as an antiseptic in various products for many years with no evidence of resistance¹⁶.

PHMB exhibits broad spectrum activity against bacteria and fungi including methicillin-resistant *Staphylococcus aureus* (MRSA), vancomycin-resistant *Enterococcus* (VRE), *Acinetobacter baumannii*, *Pseudomonas aeruginosa*, *Klebsiellas* and *Candida albicans*^{17,18}.


The antimicrobial activity of PHMB is not affected significantly by proteins contained in wound exudate and blood¹⁶ and is sustained for seven days¹⁸.

PHMB has a favourable biocompatibility index (above one) that indicates good antimicrobial activity with very little toxicity to tissue cells^{16,19}.

Figure 1 The structure of foam in Kendall™ AMD antimicrobial foam dressings. This has been designed to have a high absorptive capacity, maximum exudate retention properties and softness¹⁴ (printed with permission from Covidien)



Foam surface is designed for vertical wicking action.



Foam core for absorption and retention.

Table 1 Laboratory and clinical evidence for Kendall™ AMD antimicrobial foam dressings containing PHMB

Reference	Title	Type	Main Findings
Laboratory evidence			
McGhee D, et al. Covidien, 2009	Activity of antimicrobial dressings using clinically relevant organisms	<i>In vitro</i> study to compare the efficacy of Kendall™ AMD antimicrobial foam dressing with nine other commercially available antimicrobial foam and non-foam dressings	Under test conditions, only PHMB (Kendall™ AMD dressing) and CSH (Biopatch™, Ethicon) foam dressings showed sustained efficacy of >3.0 log reductions for seven days against <i>P. aeruginosa</i> , MRSA and VRE Most silver containing dressings exhibited variable or short-term broad spectrum activity against the three challenge organisms
Kirker KR, et al. <i>Wounds</i> 2009; 21(9):229-33	Efficacy of Kendall™ AMD Antimicrobial Foam Dressing against MRSA	<i>In vitro</i> study to evaluate the efficacy of Kendall™ AMD antimicrobial foam dressing to prevent MRSA growth within the dressing	The differences in the log counts are statistically significant, indicating Kendall™ AMD dressing was more effective in reducing the colony counts than a standard foam dressing
Shah C, et al. Covidien, 2009	Efficacy and mode of action of a new PHMB-impregnated polyurethane foam dressing	<i>In-vitro</i> and <i>in-vivo</i> testing to evaluate the efficacy of the Kendall™ AMD antimicrobial foam dressing and to illustrate the mode of action	Kendall™ AMD dressing reduced the microbial count of the eight different bacterial species tested by more than 99.9% when compared to standard foam dressings with no PHMB (see 'What is biocompatibility index' page 4) In the animal study, wounds treated with Kendall™ AMD dressing had lower bacterial counts than wounds treated without PHMB, suggesting that the PHMB impregnated foam dressing provided a protective effect
Clinical evidence			
Sibbald RG, et al. <i>Adv Skin Wound Care</i> 2011; 24(2): 78-84	Reduction of bacterial burden and pain in chronic wounds using a new polyhexamethylene biguanide antimicrobial foam dressing — clinical trial results	Multicentre, randomised double blind pilot study with leg and foot ulcers (n=45)	Kendall™ AMD dressing was a significant predictor of reduced wound superficial bacterial burden (p=0.016) at week four vs foam alone Pain reduction was also statistically significant at week two (p=0.0006) and at week four (p=0.02) in favour of Kendall™ AMD dressing Polymicrobial organisms were recovered at week four in 5.3% in the Kendall™ AMD dressing group vs 33% in the control group (p=0.04) The Kendall™ AMD dressing group had a 35% median reduction in wound size by week four, compared with 28% in the control group
Leak K, et al. <i>Wounds UK</i> 2011; 7(2): 20-25	Evaluating a dressing impregnated with polyhexamethylene biguanide	Retrospective review of patients with acute and chronic wounds treated with Kendall™ AMD antimicrobial foam dressing (n=25)	Twenty-five patients were treated in the community and use of the dressing ranged from 7-28 days Nine patients progressed to healing; the remaining 16 patients had a recorded improvement in the condition of the wound bed No new infections were recorded In the nine patients with healed wounds, use of the Kendall™ AMD dressing reduced dressing and nursing costs by a total of £167.92 per week
Warriner L, Spruce P. <i>Br J Nurs</i> 2012; Tissue Viability Suppl 21(5):S20-25	Strategy to manage overgranulation tissue around gastrostomy sites	Clinical audit on patients with percutaneous endoscopic gastrostomies (PEG)	Kendall™ AMD was observed to contribute to the reduction of overgranulation tissue around PEG sites
Sterling W, et al. <i>Wounds UK Conference</i> 2009 (Harrogate, UK)	Patient perceptions of a new antimicrobial dressing	Evaluation to determine patient rated acceptability and efficacy on chronic wounds (n=26)	Most patients reported an improvement in the condition of the wound, noting reductions in pain, drainage, odour and size, and their quality of life Five ulcers healed completely
Hagelstein SM, et al. EWMA 2009 (Helsinki)	A series of case studies investigating the performance of a new antimicrobial foam dressing	Case series: patients with chronic leg ulcers (n=12; 10 venous, 2 vasculitic)	A dramatic decrease was recorded in nine patients who reported pain at baseline The majority of wounds improved in size No patients developed infection Kendall™ AMD dressing contained exudate and controlled odour Clinicians found the dressing easy to apply and remove
Timmons J, Leak K. <i>Wounds UK</i> 2009; Supplement	PHMB: the role of Kendall™ AMD antimicrobial foam dressing (0.5% PHMB) in the treatment of wounds	Case series: patients with complex wounds with a localised infection or risk of infection (n=9)	Kendall™ AMD dressing reduced the bioburden in the wound, absorbed exudate and maintained an optimal moist wound healing environment Kendall™ AMD dressing did not cause pain or trauma on removal Patients were highly satisfied with the product When used on critically colonised / slow to heal wounds the dressing improved clinical outcomes In some cases Kendall™ AMD dressing facilitated debridement and epithelialisation
De Boer C. EWMA 2009 (Helsinki)	Managing moisture and bacterial burden in acute wounds	Case series: patients with localised infection or risk of developing infection following surgery (n=7)	Kendall™ AMD dressing controlled both gram positive and gram negative wound bacteria, including the resistant strains of MRSA
Hucker M. <i>Wounds UK Conference</i> 2009 (Harrogate, UK)	Different challenges — one solution	Case series: patients with complex wounds (n=6)	All wounds progressed towards healing Other benefits included improving patient comfort and improving periwound skin

What is the biocompatibility index?

The antimicrobial agents used on a wound surface should be sufficiently active to reduce bacterial numbers, while at the same time be minimally toxic to the newly forming wound tissue. A measure of relative antimicrobial activity and cellular toxicity is the biocompatibility index.

A biocompatibility index above one indicates good antimicrobial activity and low wound cell toxicity. Ideally, an antimicrobial agent should reduce bacterial numbers by 1,000 fold (ie 99.9% or three logarithms) while not killing the host cells^{16,19}.

What is the evidence for Kendall™ AMD antimicrobial foam dressings?

Laboratory and clinical studies (Table 1) have shown Kendall™ AMD antimicrobial foam dressing to be active against a wide range of wound pathogens and to be effective in the management of a wide range of wound types with increased bioburden.

In a recent multicentre, prospective double-blind randomised controlled clinical trial, 45 patients with locally infected chronic venous leg ulcers or diabetic foot ulcers were followed for five weeks²⁰. The patients were randomised to either a PHMB-impregnated foam dressing (Kendall™ AMD antimicrobial foam dressing) or a control foam dressing group. The study findings indicate that the PHMB foam dressing was able to significantly reduce the bacterial burden ($p=0.04$) than wounds managed with the control foam dressing. In addition, the PHMB dressings group had a 35% median reduction in wound size by week 4, compared with 28% in the control group. Pain reduction was also statistically

significant for the PHMB dressing at week 2 ($p=0.0006$) and at week 4 ($p=0.02$) compared with the control group.

Additional case series have found positive results for treatment with Kendall™ AMD antimicrobial foam dressings on patients with lower limb ulceration requiring compression²¹, following negative pressure wound therapy^{22,23}, and in older people with skin tears²⁴.

Furthermore, in a series of 25 consecutive bedridden patients (mean age 4.6 years), 90% of wounds that were treated with Kendall™ AMD antimicrobial foam dressing were healed within two weeks and a mean of 6.5 dressing changes²⁵. The wounds occurred at a range of sites, including occiput, ear, heel, back and sacrum. The dressing was well tolerated and no adverse effects, allergic reactions or periwound skin complications were observed²⁵.

When are Kendall™ AMD antimicrobial foam dressings indicated?

Kendall™ AMD antimicrobial foam dressings are indicated for a wide range of moderate to heavily exuding wounds, where the clinician suspects that the presence of microorganisms is delaying healing (Box 2).

Kendall™ AMD antimicrobial foam dressings can be used for locally infected wounds with an increased bacterial burden and may be used in conjunction with prescribed therapies for the treatment of spreading or deep infection (eg systemic antibiotics). The dressings may be used as a primary or secondary dressing for packed wounds.

Kendall™ AMD antimicrobial foam dressing discs and fenestrated dressings impregnated with PHMB are indicated for use around the sites of catheter

Box 2 Indications for Kendall™ AMD antimicrobial foam dressings (IFU, 2008)

- Pressure ulcers
 - Venous stasis ulcers
 - Diabetic foot ulcers
 - Donor sites
 - Trauma wounds, including abrasions/lacerations (eg skin tears)
 - First and second degree burns
 - Dermatological disorders with skin breakdown
 - Post-surgical incisions
 - Device exit/entry sites*, eg drains, tracheostomy, intravenous catheters, external fixation.
- * Fenestrated dressings or foam discs.

insertions (eg central venous catheters), tracheostomy sites and external fixator pin entry sites. These dressings protect against the entry of bacteria and limit the risk of cross-infection¹³.

In disc form, the dressings are also useful for the management of exudate that may occur at surgically induced exit sites wounds, eg tracheostomy sites, G- or J-tubes, Penrose drains, chest drains, nephrostomy sites, central venous lines, dialysis catheters, externally placed orthopaedic pins and epidural catheters.

Kendall™ AMD antimicrobial foam dressings can also be used in the treatment of complex wounds in paediatric patients²⁵.

Contraindications

Kendall™ AMD antimicrobial foam dressings should not be used for the treatment of full thickness burns or on patients with known sensitivity to PHMB²⁵. Patients with dry wounds, including those with eschar or scabs, should not have a foam dressing applied. In addition, wounds with light exudate should not be treated with a foam dressing because the wound may become too dry, which may inhibit the final stages of healing.

Table 2 Dressing selection guide for Kendall™ AMD antimicrobial foam dressing range Note: The non-adherent dressings require separate fixation with a film dressing, tape or an appropriate secondary dressing

Product	Composition	Method of use	Frequency of change	When to use
Kendall™ AMD antimicrobial foam dressing	Double-sided foam pad containing 0.5% PHMB (white on both sides)	Apply either white side to the wound	The dressing can be left in place for up to 7 days, depending on the wound condition	Contaminated, colonised or infected wounds with moderate to high exudate levels
Kendall™ AMD antimicrobial foam dressing with backsheet	Foam pad containing 0.5% PHMB with polyurethane back sheet to avoid fluid and bacteria strikethrough	Apply white side to the wound	The dressing can be left in place for up to 7 days, depending on the wound condition	Contaminated, colonised or infected wounds with moderate to high exudate levels. Can be used in cavity wounds
Kendall™ AMD antimicrobial foam with adhesive border	Foam pad containing 0.5% PHMB with adhesive border	Apply white side to the wound. Does not require separate fixation	The dressing can be left in place for up to 7 days, depending on the wound condition	Contaminated, colonised or infected wounds with moderate to high levels of exudate. Can be used on surface wounds where there is a need for an adhesive dressing to secure it in place
Kendall™ AMD antimicrobial foam fenestrated dressing	Foam pad containing 0.5% PHMB (standard version and with polyurethane backsheet)	If using the standard version, either either white side. If using the version with the polyurethane backsheet, ensure that the white side is applied to the wound.	The dressing can be left in place for up to 7 days, depending on the wound condition	Contaminated, colonised or infected wounds with moderate to high exudate levels. For the protection and management of exit sites
Kendall™ AMD antimicrobial foam disc	Double sided foam pad containing 0.5% PHMB available with 4mm or 7mm hole	Apply either side down, carefully placing around the catheter tubing or pin site	The discs are effective for up to 7 days can be left in place for up to one week, depending on the condition of the exit site wound	Can be used on catheter insertion sites such as central venous catheters and peripherally inserted central catheters. They can also be used around fixation sites

How to apply Kendall™ AMD antimicrobial foam dressings

Step 1: Selecting the dressing

After cleansing the wound according to local policy, the surrounding skin should be assessed. If there are any signs of fragility, sensitisation, maceration, oedema, eczema, atrophe blanche, excoriation, cellulitis or lymphoedema, consideration should be given to the size of the dressing and whether a version of the dressing with an adhesive border or protective backsheet should be used. If the dressing is to protect an entry or exit site, a fenestrated dressing or foam disc may be most appropriate (see Table 2).

Step 2: Applying the dressing

The dressing should have a 5cm (2 inch) foam margin around the wound and can be cut to size. The dressing should

be placed with the white side touching the wound surface and/or with the polyurethane backsheet facing up.

The dressing can be secured with a retention bandage or tape. If using the adhesive bordered dressing, it may be advisable to use a skin protectant on the surrounding skin if the patient has had previous irritation from dressings or will have repeated use of an adhesive dressing on the skin.

Frequency of dressing changes

Kendall™ AMD antimicrobial foam dressings may stay in place for up to seven days between dressing change²⁶. The frequency of dressing change will depend on the level of exudation. If there are signs of exudate towards the edge of the dressing, this indicates that

a dressing change is required. Bulging or expansion of the dressing is normal and is due to the absorption of exudate into the dressing.

Removing the dressing

After removal of the bandages or tape, the dressing may be gently removed. Kendall™ AMD antimicrobial foam dressings are non-adherent and should not leave any residue in the wound or on the surrounding skin.

When to discontinue Kendall™ AMD antimicrobial foam dressings?

The dressings should be discontinued when exudate becomes light and/or the signs of localised infection have resolved. However, if the patient has a history of recurrent infection, the

dressing can be used to minimise the risk of recurrent local infection.

What are the cost benefits?

In a retrospective review of 25 patients treated as outpatients with Kendall™ AMD antimicrobial foam dressings, nine of the wounds healed during the 7–28 days of treatment²⁶. In the remaining 16 patients a reduction in devitalised tissue and an improvement in the condition of the wound bed was noted. Twenty-four patients reported the overall comfort of the dressing to be 'good' or 'very good'. When the cost of dressings and nursing time was calculated for each of the nine patients whose wound had healed, the cost for seven patients was less with the Kendall™ AMD antimicrobial foam dressing with an overall saving of £167.92 (\$ US 270; 207 EUR*) per week²⁷.

*At current exchange rates as of 30/4/2012

References

1. Percival S. Understanding the effects of bacterial communities and biofilms on wound healing. *World Wide Wounds* 2004. Available from: <http://www.worldwidewounds.com/2004/july/Percival/Community-Interactions-Wounds.html>
2. James GA, Swogger E, Wolcott R, et al. Biofilms in chronic wounds. *Wound Repair Regen* 2008; 16(1): 37–44.
3. Phillips PL, Wolcott RD, Fletcher J, Schultz GS. Biofilms Made Easy. *Wounds International* 2010; 1(3): Available from <http://www.woundsinternational.com>
4. Serralta VW, Harrison-Balestra C, Cazzaniga AL, et al. Lifestyles of bacteria in wounds: presence of biofilm? *Wounds* 2001; 13(1): 29–34.
5. Vowden P, Vowden K. Antimicrobials Made Easy. *Wounds International* 2011; 2(1): Available from <http://www.woundsinternational.com>
6. Bowling FL, Stickings DS, Edwards-Jones V, et al. Hydrodebridement of wounds: effectiveness in reducing wound bacterial contamination and potential for air bacterial contamination. *J Foot Ankle Res* 2009; 8; 2: 13.
7. Wolcott RD, Rumbaugh KP, James G, et al. Biofilm maturity studies indicate sharp debridement opens a time-dependent therapeutic window. *J Wound Care* 2010; 19(8): 320–28.
8. Sibbald RG, Woo K, Ayello E. Increased bacterial burden and infection: NERDS and STONES. *Wounds UK* 2007; 3(2): 25–46.
9. World Union of Wound Healing Societies (WUWHS). *Principles of best practice: Wound infection in clinical practice. An international consensus*. London: MEP Ltd, 2008.
10. Gardner SE, Frantz RA, Doebbeling BN. The validity of the clinical signs and symptoms used to identify localized chronic wound infection. *Wound Repair Regen* 2001; 9(3): 178–86.
11. Edmonds ME, Foster AVM. Diabetic foot ulcers: ABC of wound healing. *BMJ* 2006; 332(7358): 407–10.
12. Timmons J, Leak K. PHMB: the role of Kendall™ AMD antimicrobial foam dressing (0.5% PHMB) in the treatment of wounds. *Wounds UK* 2009; Supplement.
13. Spruce P, Warriner L, Keast D, et al. Exit Site Wounds Made Easy. *Wounds International* 2012. Available from: www.woundsinternational.com
14. Shah C, Hansen P, Swaniker P, et al. Efficacy and mode of action of a new PHMB impregnated polyurethane foam dressing. Data on file, Covidien 2009.
15. Gilbert P, Moore LE. Cationic antiseptics: diversity of action under a common epithet. *J Appl Microbiol* 2005; 99: 703–15.
16. Hübner N-O, Kramer A. Review on the efficacy, safety and clinical applications of polihexanide, a modern wound antiseptic. *Skin Pharmacol Physiol* 2010; 23(suppl 1): 17–27.
17. Kirker KR, Fisher ST, James G. Efficacy of Kendall™ AMD Antimicrobial Foam Dressing against MRSA. *Wounds* 2009; 21(9): 229–33.
18. McGhee D, Bade D, Shah C. Activity of antimicrobial dressings using clinically relevant organisms MRSA, VRE, and P. aeruginosa. Mansfield, MA (USA): Covidien, 2009. <http://www.kendallhq.com/imageServer.aspx?contentID=14302&contentType=application/pdf> [accessed 15 February 2012].
19. Müller G, Kramer A. Biocompatibility index of antiseptic agents by parallel assessment of antimicrobial activity and cellular cytotoxicity. *J Antimicrob Chemother* 2008; 61(6): 1281–87.
20. Sibbald RG, Coutts P, Woo KY. Reduction of bacterial burden and pain in chronic wounds using a new polyhexamethylene biguanide antimicrobial foam dressing — clinical trial results. *Adv Wound Care* 2001; 24(2):78–84.
21. Stanway S. A review of a foam dressing containing 0.5% polyhexamethylene biguanide under compression therapy in the management of lower limb ulceration. Peer reviewed poster presentation Wounds UK Conference, Harrogate, 2009.
22. Leak K, Spruce P, Johnson S. Improving outcomes for patients following surgery for breast cancer. *Wounds UK* 2009; 5(3): 47–55.
23. Leak K, Johnson S, Spruce P. An evaluation of 4 patients post negative pressure wound therapy using a foam dressing containing 0.5% polyhexamethylene biguanide (PHMB). Wounds UK Harrogate, 2009.
24. Bateman S. Treating skin tears with a new antimicrobial foam dressing. *Wounds UK* 2012; 8(1): 95–9.
25. Ciprandi G. Palliative wound care in pediatric patients. 21st Conference of the European Wound Management Association, EWMA 25–27 May 2011.
26. Kendall™ Antimicrobial Foam Dressing Instructions for Use. Mansfield, MA (USA): Covidien 2008. Available from: <http://www.kendallhq.com/imageServer.aspx?contentID=14301&contentType=application/pdf> [accessed 15 February 2012].
27. Johnson S, Leak K. Evaluating a dressing impregnated with polyhexamethylene biguanide. *Wounds UK* 2011; 7(2): 20–25.

This 'made easy' is supported by educational grant from Covidien. For further information please go to www.kendallamdfoam.com

Author details

Spruce P¹, Edwards-Jones V², Ivins N³, Sibbald RG⁵, Shah C⁶, Patel H⁷,

1. Clinical Director, TVRE Consulting, Stoke on Trent, UK
2. Professor of Microbiology, Manchester Metropolitan University, UK
3. Clinical Trials Manager, Wound Healing Institute for Translation, Innovation, Methodologies and Engagement (TIME), Cardiff University, UK
4. Associate Professor of Internal Medicine, University of Toronto, Canada
5. Senior Director, Bioscience R&D, Covidien, USA
6. Director, R&D, Nursing Care Products, Covidien, USA

Summary

Kendall™ AMD antimicrobial foam dressings are highly absorbent foam dressings that contain PHMB, an effective topical antimicrobial agent that has very low cytotoxicity. These dressings can be used for up to seven days and are available in a variety of useful formulations. They are suitable for the management of localised infection in a wide range of acute and chronic wounds, and for the prevention of microbial entry at percutaneous entry or exit sites.

To cite this publication

Spruce P, Edwards-Jones V, Ivins N, Ciprandi G, Sibbald RG, Shah C, Patel H. Kendall™ AMD Antimicrobial Foam Dressings Made Easy. *Wounds International* 2012; 3(2): Available from <http://www.woundsinternational.com>