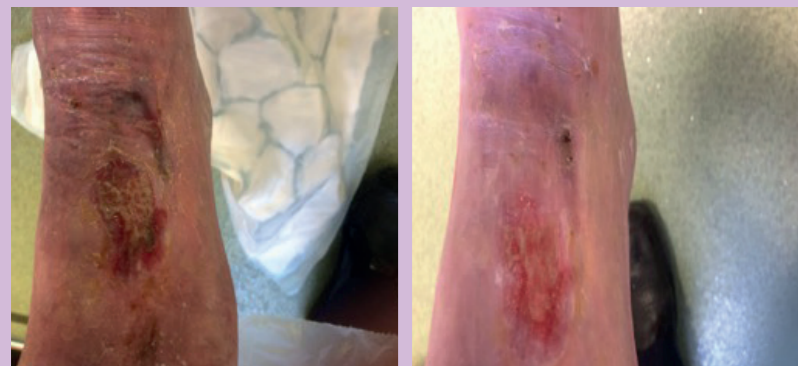
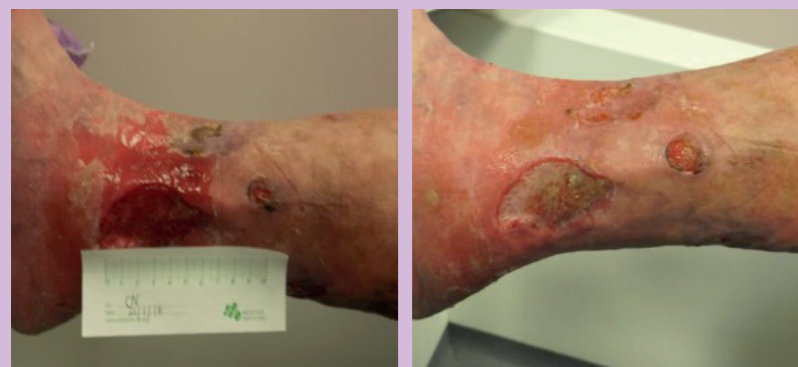
### Case study 2



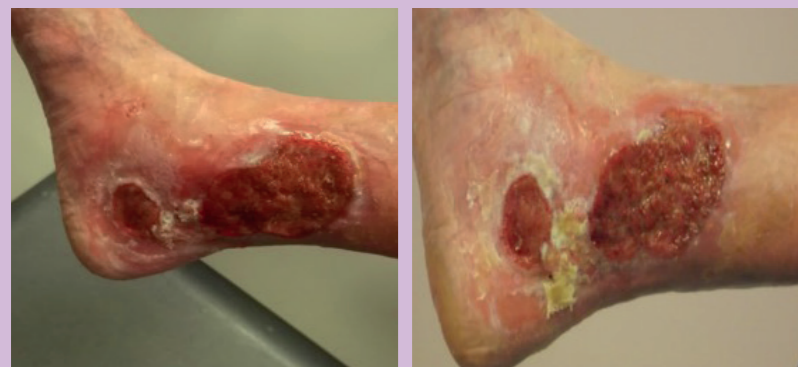a) Wound at week 1, before treatment with Zorflex  
b) Wound at week 4, after three dressing changes

### Case study 3



a) The wound before treatment with Zorflex activated charcoal cloth  
b) Week 4. Unfortunately by this time a new ulcer appeared on the front of the leg.

### Case study 4



a) The wound at week 1  
b) Week 2

### Case study 3

A 56-year-old patient with learning difficulties had a painful non-healing ulcer on the lower gaiter of the right leg. An assessment was carried out that showed triphasic pulses to the dorsalis pedis and posterior tibia. The patient could not tolerate the hand-held Doppler so a sonography test was used instead. Her pain level was high (VAS score: 6). The wound had been present for 8 months' duration and originally measured 7 cm x 4 cm; the wound bed was red and inflamed with areas

of slough approximately 40% with areas of granulation but these had become static. Large amounts of exudate from the wound were present, which often broke through onto the compression bandages. The exudate caused excoriation to the peri-wound area and increased the patient's pain level. Hyperkeratosis was present on the rest of the limb. The peri-wound skin was excoriated and tender to touch. The exudate level not well controlled. Long-term antimicrobials including silver, honey, PHMB and DACC, were all used on a rotation basis of 2 weeks on one dressing then changed to another, unfortunately without much success, which did not help the patient's mood as she would often become anxious about the lack of progression in the wound. However, as soon as all the antimicrobial dressings were discontinued, the wound became critically colonised, producing large volumes of exudate. The wound's failure to respond to treatment was causing the patient considerable anxiety.

After 7 days of treatment with Zorflex, with a superabsorbent as the secondary dressing (to manage the high exudate levels) and two layers of short-stretch compression bandages, the excoriation had resolved and was no longer an issue, and there were visible signs of granulation tissue. The VAS score had reduced to 4.

After 4 weeks of treatment, there was an overall reduction in wound size. The wound width was now 3 cm x 4 cm and there were visible signs of improvement to the peri-wound area. The peri-wound excoriation had completely resolved and the patient was not reporting any pain.

'I am now in compression hosiery which I have not been able to use in the past due to the exudate levels. This has helped me to feel more confident about going out to my social clubs and shopping.'

Mrs N

### Case study 4

A 88-year-old woman had a history of venous leg ulceration. Previous treatments had included Flaminal (alginogel dressing), which had resulted in healing in 2013. She had a history of chronic, non-healing VLU that were prone to infection. She routinely wore compression therapy, and usually changed from bandages to hosiery depending on exudate level.

The new episode of ulceration occurred 3 months prior to Zorflex being used. As the wound responded well to Flaminal in the past this was used but on this particular occasions was not successful. The wound showed signs of localised infection and so was treated with antimicrobial dressings containing silver—PHMB-containing dressings had also been used in the past. However, as soon as the wound improved and the antimicrobial dressing was discontinued the wound deteriorated. The wound was very painful (VAS score: 7) and was producing high volumes of exudate, which was causing peri-wound maceration. There were also signs of over-granulation. The family was worried that the wound was not improving, while the patient's main concerns were the recurrent infections and signs of over-granulation. The patient was attending a specialist ulcer clinic twice a week, and the decision was made to use Zorflex.

After 7 days of treatment with Zorflex, the over-granulation

on the base of the wound bed had reduced and the VAS pain score had reduced to 2. The maceration to the peri-wound area had improved and no longer visible (see *Case study 4, picture b*). Unfortunately, the patient was admitted to hospital for an unrelated chest infection, and Zorflex was not used during the admission. However, it was planned to resume use of Zorflex following the patient's discharge (due to the hospital admission there was no 4-week review at the ulcer clinic).

### Outcome

In all four of the evaluations patients reported a decrease in their pain level and clinicians noted exudate levels reduced and overall wound bed appearance improved within a 7-day period. All four patients remain on Zorflex as continued improvement is noted at each dressing change.

### Conclusion

Chronic wounds may necessitate lifestyle changes and lead to several physical consequences but careful assessment and patient-centred care planning can reduce the burden these chronic wounds present to both patient and health professional. The use of topical antimicrobials in managing these wounds can support this and should be based on ongoing assessment of patient and the wound (Gethin, 2009). Zorflex wound contact dressing, when applied directly to chronic wounds, improved the appearance of the wound bed, reduced exudate levels and pain and clinic visits all within a 7-day period. The clinical signs of infection including erythema, odour, and slough in the wound bed all reduced within a short period of time, improving the overall patient experience in managing their chronic wounds. This also helped to optimise wound care resources and reduce costs in managing these patients as they were all able to decrease clinic visits and amount of dressings used and three out of the four were placed into compression hosiery.

Chronic wounds are both costly to patients and the NHS. In order to manage these wounds effectively a new ways of treating them needs to be found. Zorflex offers patients and staff the effectiveness of an antimicrobial dressing that manages odour, exudate and reduces pain all within an average period of 7 days. **BJN**

*Declaration of interest: this article was supported by Chemiviron Carbon*

Chemiviron Carbon (2015) *Clinical Focus: Zorflex® VB-K antimicrobial, wound dressings*. Chemiviron Carbon, Houghton le Spring (available on request)  
Cooper RA, Bjarnsholt T, Alhede M (2014) Biofilms in wounds: a review of present knowledge. *J Wound Care* 23(11): 570–82. doi: 10.12968/jowc.2014.23.11.570  
Gethin G (2009) Role of topical antimicrobials in wound management. *Journal of Wound Care/Active Supplement* 2009: 4–8  
Gethin G, Crocett P, Probst S, Clarke E (2014) Current practice in the management of wound odour: an international survey. *Int J Nurs Stud* 51(6): 865–74. doi: 10.1016/j.ijnurstu.2013.10.013  
Gotttrup F, Apelqvist J, Bjarnsholt T et al (2013) EWMA Document: Antimicrobials and Non-healing Wounds—Evidence, Controversies and Suggestions. *J Wound Care* 22(suppl 5): S1–S89. doi: 10.12968/jowc.2013.22.Sup5.S1  
Hurlow J, Bowler PG (2009) Clinical experience with wound biofilm and management: a case series. *Ostomy Wound Manage* 55(4): 38–49  
James GA, Swogger E, Wolcott R et al (2008) Biofilms in chronic wounds. *Wound Repair Regen* 16(1): 37–44  
Kingsley A (2001) A proactive approach to wound infection. *Nurs Stand* 15(30):

### KEY POINTS

- Most antimicrobial dressings work by killing bacteria and are indicated for use only when there are clear signs of increased bioburden and/or clinical signs of infection
- Zorflex activated charcoal cloth dressing works by attracting and binding microorganisms to its surface, so they are removed from the wound at dressing change
- Dressings that physically bind to bacteria can be used safely for long periods, making them suitable for prophylactic and therapeutic purposes
- Case-study evidence has shown the use of Zorflex resulted in reduction in clinical signs of infection including exudate and pain levels, and improvement in the appearance of the wound bed

50–8  
Lee BY (2005) *The Wound Management Manual*. McGraw-Hill, London  
Lee G, Anand SC, Rajenaran S (2009) Are biopolymers potential deodorising agents in wound management? *J Wound Care* 18(7): 290–95. doi: 10.12968/jowc.2009.18.7.4312  
Lenselink E, Andriessen A (2011) A cohort study on the efficacy of a polyhexanide-containing bio-cellulose dressing in the treatment of biofilms in wounds. *J Wound Care* 20(11): 536–9  
Martin M (2013) Physiology of wound healing. In: Flanagan M (ed.) *Wound Healing and Skin Integrity: principles and practice*. Wiley-Blackwell, New Jersey  
Metcalf DG, Bowler PG, Hurlow J (2014) A clinical algorithm for wound biofilm identification. *J Wound Care* 23(3): 137–42. doi: 10.12968/jowc.2014.23.3.137  
Parel S (2007) *Wound Essentials 2: Understanding wound infection and colonisation*. Wounds UK, London  
Percival SL, Bowler PG (2004) Biofilms and their potential role in wound healing. *Wounds* 16(7): 234–40. http://tinyurl.com/h3nzsb (accessed 25 April 2016)  
Phillips P, Sampson E, Yang Q, Antonelli P, Proguiske-Fox A, Schultz G (2008) Bacterial biofilms in wounds. *Wound Healing Southern Africa* 1(2): 10–12  
Percival SL, Suleman L (2015) Slough and biofilm: removal of barriers to wound healing by desloughing. *J Wound Care* 24(11): 498–510. doi: 10.12968/jowc.2015.24.11.498  
Rajpaal K (2015) Biofilm in wound care. *Br J Comm Nurs* 20(3 suppl): S6–11. doi: 10.12968/bjcn.2015.20.Sup3.S6  
Stotts NA (2004) Wound infection: diagnosis and management. In: Morrison MJ, Ovington LG, Wilkie K (eds.) *Clinical wound care: A problem-based learning approach*. Elsevier, Philadelphia: 101–6  
Tadej M, Knowles A, Hampton S (2013a) An evaluation of the Zorflex® carbon fibre dressing in managing bacterial load and aiding healing of chronic wounds. Poster presentation at *EWMA 2013* (23rd annual congress of the European Wound Management Association), 15–17 May, Copenhagen  
Tadej M, Bree-Aslan C, Hampton S, Knowles A (2013b) The irresistible force of long fibre activated carbon cloth on colonised wound outcomes. Oral abstract presentation at *EWMA 2013* (23rd annual congress of the European Wound Management Association), 15–17 May, Copenhagen.  
van der Borden AJ, van der Mei HC, Busscher MJ (2004) Electric-current-induced detachment of *Staphylococcus epidermidis* strains from surgical stainless steel. *J Biomed Mater Res B: Appl Biomater* 68(2): 160–4  
Vowden KR, Vowden P (2006) Preventing venous ulcer recurrence: a review. *Int Wound J* 3(1): 11–21  
Walker M, Metcalf D, Parsons D, Bowler P (2015) A real-life clinical evaluation of a next-generation antimicrobial dressing on acute and chronic wounds. *J Wound Care* 24(1): 11–22. doi: 10.12968/jowc.2015.24.1.11  
White R (2009) Wound infection—associated pain. *J Wound Care* 18(6): 245–9. doi: 10.12968/jowc.2009.18.6.42803  
White R, Cutting KF (2006) Modern exudate management: a review of wound treatments. *World Wide Wounds* September. http://tinyurl.com/6ctloz (accessed 25 April 2016)  
Wolcott R (2015) Disrupting the biofilm matrix improves wound healing outcomes. *J Wound Care* 24(8): 366–71. doi: 10.12968/jowc.2015.24.8.366  
Wolcott RD, Rhoads DD, Bennett ME et al (2010) Chronic wounds and the medical biofilm paradigm. *J Wound Care* 19(2): 45–53. doi: 10.12968/jowc.2010.19.2.46966  
World Union of Wound Healing Societies (2009) *Principles of best practice: compression in venous leg ulcers. A consensus document*. October. MEP Ltd, London  
Wounds UK (2013) *Best practice statement. The use of topical antimicrobial agents in wound management*. Wounds UK, London. http://tinyurl.com/4yxcvz88 (accessed 25 April 2016)  
Young S, Hampton S (2016) A retrospective study to evaluate the effect of activated carbon dressing on chronic wounds. Poster presentation at *TFS 2016* (annual conference of the Tissue Viability Society), Cardiff, 21–20 April.

h&r healthcare  
delivering innovation

T: +44 (0)1482 631606  
www.hrhealthcare.co.uk/zorflex

ZOR03-1

# Reducing infection in chronic leg ulcers with an activated carbon cloth dressing

Nina Murphy

### ABSTRACT

Zorflex is a new type of antimicrobial dressing composed of 100% activated carbon cloth. It attracts and binds bacteria to its surface, enabling them to be safely removed at dressing change. It has no reported toxic effects and can be used on either a short- or long-term basis. This article describes 4 case studies in which patients with recalcitrant chronic venous leg ulcers that were prone to recurrent infection were treated with the activated carbon cloth dressing. All of the wounds had failed to respond to antimicrobial dressings containing silver, iodine or polyhexamethylene biguanide (PHMB), and were heavily exuding and painful. In all cases, the signs of infection reduced significantly within 4 weeks, resulting in good patient outcomes.

**Key words:** Venous leg ulcer ■ Infection ■ Activated charcoal ■ Pain ■ Exudate

Chronic wounds are likely to have an increased bioburden, which in turn increases the risk of local infection. Indeed, infection is one of the most frequent complications of non-healing wounds, resulting in longer treatment times, increased risk of morbidity, greater resource use (of both dressings and nurse time) and, most importantly, a high personal cost to patients and their families (Cooper et al, 2014). While the ultimate aim is to treat the underlying wound, use of antimicrobial dressings is the cornerstone of the treatment of infected wounds. Most antimicrobial dressings work by killing the bacteria, and are indicated for use only when there are clear signs of increased bioburden and/or clinical signs of infections. As such, their use is assessed after 2 weeks, at which point it is advised that the clinician switches to another type of dressing if the wound is observed to be healing (Cooper et al, 2014).

This article describes a new type of antimicrobial dressing that is composed of 100% activated charcoal cloth. This dressing achieves its effect by attracting and binding bacteria and fungi to its surface, so that the microorganisms are removed from the wound at dressing change (Chemiviron Carbon, 2015). As a result, it can be safely used for prolonged period, with no risk of toxicity to the patient or microbial resistance (Chemiviron Carbon, 2015). This article describes the preliminary case-study evidence on the effectiveness of this new antimicrobial dressing.

### Bioburden and non-healing

The skin is host to a large number of bacteria. Most of these bacteria are commensals, which means they co-exist with the host and will not cause any problems (Lee, 2005). Some, such as *Staphylococcus aureus*, have the potential to become

pathogens. If the skin is broken, the bacteria will contaminate the newly formed wound (Martin, 2013). Contamination refers to the presence of microorganisms on the wound bed, where the bacteria do not increase in number and therefore do not impair healing (Stotts, 2004; Patel, 2007). The wound becomes colonised when multiple microorganisms are present on the skin, but there is still no damage to wound tissue and no clinical signs of a host reaction (Martin, 2013). Heavier colonisation (sometimes referred to as critical colonisation) occurs when the host's immune system is no longer able to keep the bacterial proliferation in check. Such wounds are likely to become chronic, with the wound becoming stuck in a prolonged inflammatory state, but not necessarily showing overt signs of local infection (Kingsley, 2001). It is only when the bacterial species have multiplied to the extent that this results in damage to the wound tissue that an infection is considered to have occurred. Localised infection is limited to the wound and its margins, and is characterised by the clinical symptoms caused by the ensuing host response (Table 1). If the multiplying bacteria overwhelm the immune response, a systemic infection can occur.

Wound biofilms are widely regarded as precursors to infection (Percival and Bowler, 2004). A wound biofilm occurs when planktonic (i.e., solitary, non-attached and free floating) bacteria attach to a wound surface to form a polymicrobial community that is protected by a slimy extracellular polymeric substance (EPS). The biofilm matures within 2–4 days of attachment, when it becomes resistant to antibiotics and antimicrobial agents (Cooper et al, 2014). The biofilm is thought to trigger an inflammatory response, with the innate immune system prompting the release of neutrophils and macrophages and then high levels of matrix metalloproteinases (MMPs) and reactive oxygen species in a bid to remove the colony (Phillips et al, 2008). These cytokines and proteases will also harm any healthy or healing tissue. The mature biofilm, encased in its protective EPS, steadily becomes more resistant to the host immune system (Wolcott et al, 2010).

The biofilm therefore places the wound in a state of prolonged inflammation, with the ensuing elevated levels of cytokines and proteases resulting in the degradation of wound tissue. The resulting increase in devitalised tissue creates an ideal environment for bacterial growth. James et al (2008)

Nina Murphy, Clinical Nurse Specialist Tissue Viability, NELFT Community Services, NELFT NHS Foundation Trust, London

Accepted for publication: April 2016

reported that biofilms have been identified in up to 60% of chronic wounds compared with only 6% of acute wounds.

It is thought that the term critical colonisation actually refers to a chronic wound in which a biofilm is present. It could be argued, therefore, that the infection continuum comprises: contamination, colonisation, biofilm development, spreading infection and systemic infection (Rajpaul, 2015). The most effective way of removing a wound biofilm is with regular surgical or mechanical debridement, followed by cleansing with an antiseptic irrigation solution and the use of an antimicrobial dressing (Lenselink and Andriessen, 2011; Walker et al, 2015; Wolcott, 2015).

As described above, chronic wounds are characterised by an increased bioburden, biofilm and prolonged inflammation. Drug-resistant strains of bacteria are often present. Chronic wound exudate contains high levels of MMPs, which degrade protein, enzymes and growth factors, thereby causing further tissue breakdown and prolonging the inflammatory state (White and Cutting, 2006). This, in turn, will increase the amount of devitalised tissue (necrotic tissue and slough) present in the wound bed. As the tissue in the wound bed deteriorates and breaks down, exudate production increases, particularly if the wound increases in size. Increased exudate production is associated with malodour (James et al, 2008). The presence of devitalised tissue and chronic wound exudate all contribute to delayed or non-healing. Devitalised tissue and exudate are sources of nutrients to bacteria and provide an ideal environment for bacterial proliferation (Martin, 2013).

It is proposed that slough and excess exudate volumes are by-products of biofilm formation as they are direct consequences of the prolonged inflammation that the polymicrobial colony induces (Percival and Suleman, 2015). It is vital therefore that any slough, necrotic tissue and excess exudate are removed as part of the strategy to control the wound bioburden. Devitalised tissue will need to be debrided and antimicrobial agents applied to control the bacterial growth. However, this will only be successful if the underlying wound aetiology is diagnosed as part of a holistic patient assessment and the correct gold standard treatment, such as compression for venous leg ulcers and offloading for diabetic foot ulcers, is applied.

**Assessment**

Early detection that the wound is not responding to standard treatment in a timely fashion, followed by reassessment of the management strategy and the wound aetiology, will improve the likelihood of a good patient outcome (White, 2009). Assessment of a non-healing wound requires a good understanding of the patient risk factors associated with increased bioburden and prolonged inflammation, as well as the physiological causes of slow or non-healing described above. Patient risk factors include obesity, malnutrition, old age and restricted mobility, alcohol or drug misuse (Vowden and Vowden, 2006). Comorbidities that can impair the immune response include diabetes, immunocompromised status and conditions, such as anaemia or arterial/cardiac/respiratory disease, that reduce perfusion or cause hypoxia, malignancy and rheumatoid arthritis (World Union of Wound Healing

Table 1. Signs and symptoms to look for in clinically infected wounds	
Local infection	<ul style="list-style-type: none"> <li>■ Unexpected/new pain or tenderness</li> <li>■ Delayed healing</li> <li>■ Peri-wound oedema</li> <li>■ Erythema</li> <li>■ Heat</li> <li>■ Malodour</li> <li>■ Increase in exudate</li> <li>■ Fragile/bleeding granulation tissue</li> <li>■ Induration</li> <li>■ Pocketing</li> </ul>
Spreading infection	<ul style="list-style-type: none"> <li>■ Spreading erythema</li> <li>■ Wound breakdown</li> <li>■ Malaise and general deterioration in patient's health</li> <li>■ Raised temperature</li> <li>■ Nausea/sickness</li> </ul>

Source: Adapted from WUWHS, 2009

Societies (WUWHS), 2009). Diagnosis of wound infection is based on the presence of clinical signs and symptoms. A wound swab should only be taken to identify if certain pathogens are present, and at what density, in order to inform treatment options. There is some debate about whether wound biofilm can be seen with the naked eye, with some saying it is microscopic and others that it can form a translucent, slimy layer on the chronic wound or a more opaque, green-yellow substance on the wound surface (Hurlow and Bowler, 2009; Metcalf et al, 2014). Metcalf et al (2014) published an algorithm to aid identification of wound biofilm.

The psychological effects of the non-healing wound on the patient must also be considered. The release of proteolytic enzymes and inflammatory mediators can result in irritation of the nerve endings, causing increased pain (Gethin, 2009; Cooper, 2011). Pain, along with excess exudate, the ensuing risk of strikethrough, reduced mobility and malodour can have a negative effect on wellbeing and quality of life, restricting aspects of day-to-day living and social interaction. This can result in low mood, stress and even depression (White, 2009).

**Management**

Systemic wound infection must be treated with antibiotics. If the wound is critically colonised or a biofilm is suspected (for example, there are moderate levels of malodorous slough and exudate), or there are signs of local infection, the wound should be cleansed and afterwards an antimicrobial dressing should be applied.

A wide range of antimicrobials dressings are available. These dressings inhibit bacterial growth or division either by killing the bacteria or by binding to the microorganisms by killing the bacteria or by binding to the microorganisms so that they can be physically removed from the wound at dressing change. They can be used when there are clinical signs of infection or clinical indications that the bioburden is interfering with healing (Wounds UK, 2013). Antibacterial agents contained within dressings that cause bacterial cell death include silver, honey, iodine and polyhexamethylene biguanide (PHMB). They bind to bacterial cell DNA or damage the cell membranes (Gottrup et al, 2013). In contrast, dressings containing dialkylcarbamoylchloride (DACC) attract and irreversibly bind microorganisms to the surface of the dressing, removing bacteria and fungi

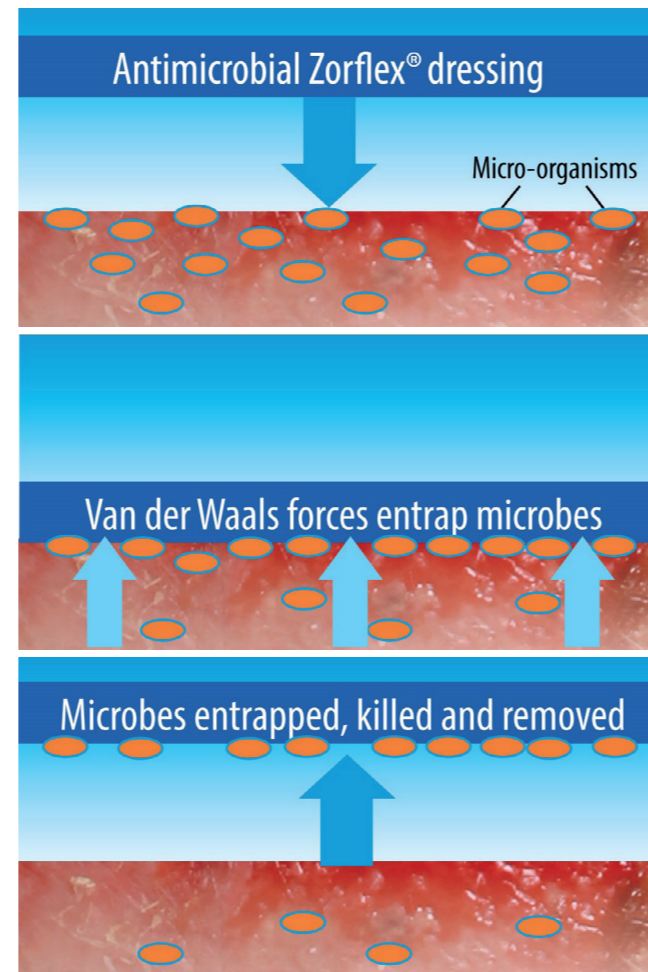


Figure 1. Diagram of the Van der Waals trapping theory (Chemviron Carbon, 2015)

from the wound at dressing change (Wounds UK, 2013). The use of antimicrobial dressing should be assessed after 2 weeks. Silver dressings should not be used for longer than 4 weeks without good clinical rationale (Wounds UK, 2013). Dressings that physically bind to bacteria can be used safely for long periods, making them suitable for prophylactic and therapeutic purposes (Kingsley, 2001).

**Zorflex**

Zorflex is an antimicrobial dressing, comprising 100% activated carbon cloth, which binds bacteria to its structure. It uses carbon derived from a natural source, with no chemical additives, and so is safe to use for as long as the wound remains inflamed or locally infected (Chemviron Carbon, 2015).

Activated carbon cloth has been used in wound care for many years to manage malodour (Tadej et al, 2013a), which is associated with infected, heavily exuding wounds. The malodour itself is caused by volatile molecules including acids (n-butyric, n-valeric and n-caproic), cadaverine and putrescine, that are produced by bacteria. These molecules evaporate and reach receptors in the nose that register the offensive smell (Lee et al, 2009; Gethin et al, 2014). Activated charcoal reduces malodour by a process known as adsorption (not to be confused with absorption) whereby the volatile molecules are attracted to and bind to vast numbers of microscopic pores on the surface area of the dressing.

Molecules can attract each other at moderate distances and repel each other at close range. The attractive forces are collectively known as Van der Waals, these are much weaker than chemical bonds and random thermal motion around room temperature can usually overcome or disrupt them. These Van der Waals forces are the process by which the activated charcoal physically binds molecules and materials.

Zorflex uses this same process to entrap bacteria, which are subsequently removed at dressing change (Figure 1). Van der Waals forces are one of the methods that bacteria use to bind to a surface (van der Borden et al, 2004). Bacterial cells are too large to be bound to the microscopic pores in the same way that are volatile molecules. Instead, the bacterial cells are drawn to and held onto the surface of the cloth by an electrostatic tension emanating from the Van der Waals forces. The electrostatic tension builds up in the cell until it overcomes the tensile strength of the cell wall and ruptures. The cell's endotoxins are drawn into the micropores, and not released back into the wound bed.

The production process for activated carbon cloth results in a surface area containing immense numbers of microscopic pores, making the material highly adsorptive to certain molecules. It is proposed that the activated carbon cloth is able to bind sufficient quantities of microorganisms to its structure to reduce the wound bioburden. Unpublished in vitro studies have demonstrated the bacterial sequestration, viral sequestration and retention capabilities of Zorflex (against *Staphylococcus aureus*, *Pseudomonas aeruginosa*, *Candida albicans* and a bacteriophage (tests conducted by Perfectus Biomed, October 2015, data on file). Other in vitro work has demonstrated the dressing's ability to modulate elastase (tests conducted by Perfectus Biomed, August 2015, data on file). An unpublished Health Protection Agency (HPA) report in 2009 has demonstrated the non-toxic antiviral and antibacterial properties of Zorflex.

Zorflex differs from other activated carbon dressings in its structure, which comprises long staple fibres that are twisted into a yarn, which in turn is knitted into a double-jersey textile. This interconnects all the fibres and provides an enhanced effect over carbons that are more particulate in nature. This gives the dressing antimicrobial properties not possessed by other activated carbon dressings.

Zorflex is a light, vapour-permeable, flexible fabric that can be cut to fit the size and shape of the wound. It is recommended that the dressing be changed every 7 days. It does not contain any additives and can be safely used as a prophylaxis, for as long as required, on patients at risk of infection; it is also safe to use on children and pregnant women. Any exudate will pass through the cloth to a secondary dressing. Zorflex is available on the Drug Tariff.

As yet, evidence on Zorflex comprises individual case studies, presented in a poster format, showing its ability to manage local infection and reduce bioburden in patients with chronic wounds (Tadej et al, 2013a). Its efficacy has also been demonstrated in a case series involving 10 patients with infected wounds, where its use resulted in reduction in clinical signs of infection including exudate and pain levels (Tadej et al, 2013b). Its efficacy for hard-to-heal wounds was demonstrated in a retrospective study of 20 patients measuring healing,

odour, pain and ultrasound assessment, which showed new healing tissue forming rapidly and populating the wound area with 18 patients achieving full closure after 5 weeks' treatment (Young and Hampton, 2016).

The following case studies describe use of Zorflex on chronic venous leg ulcers

**Case study 1**

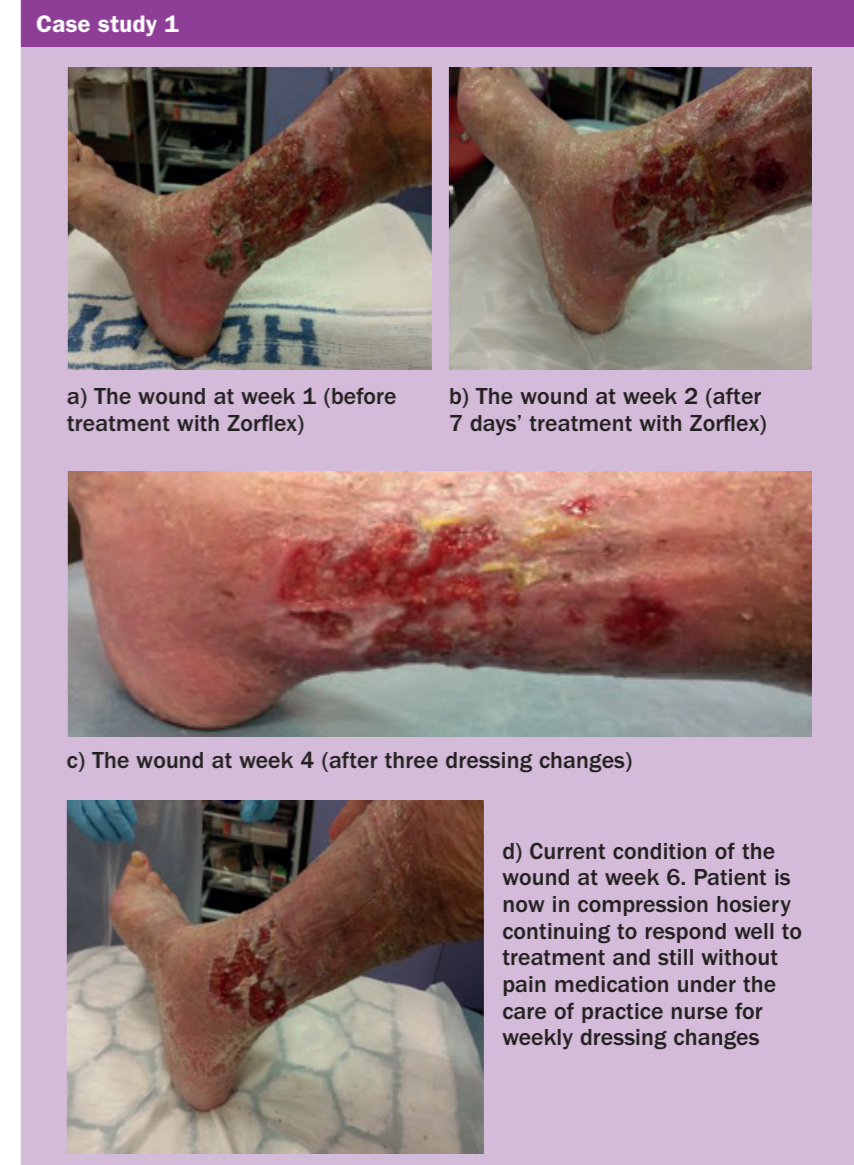This case study concerns a 92-year-old woman with a history of hypertension and osteoporosis. She had a circumferential, heavily exuding venous leg ulcer of over 6 months' duration, an ankle-brachial pressure index (ABPI) test was performed and showed a result of 0.9 on the ulcerated leg. The wound, which measured 13 cm x 11 cm, was covered with patches of green malodorous slough and was extremely painful (visual analogue score (VAS): 7), while the edges were inflamed. The patient attended the specialist clinic twice a week for management of the venous leg ulcer. The clinic liaised with the GP to change the patient's pain medication to oral gabapentin as the pain appeared to be associated more with nerve pain rather than general wound pain. This was prescribed at a low dose to be taken initially at night and increased to every 4 hours as the one dose daily did not manage the pain effectively. The wound had previously been treated with antimicrobial dressings containing silver or PHMB. The previous dressings had managed to lift some of the sloughy tissue but she found the use of these particular dressings had not managed the exudate levels effectively. Initially compression bandages were not used due to the pain in the leg. Once the pain medication had been reviewed the clinic managed to use a short-stretch bandage on the leg, which did also help with the wound; as the wound and exudate levels reduced the patient was placed in compression hosiery. At the initial stages of treatment debridement was hard for the patient to tolerate and warm tap water was used to gently wash over the wound bed removing any loose debris.

After 7 days of treatment with Zorflex, a superabsorbent and compression therapy, the wound reduced to 10 cm x 12 cm with no strikethrough on the secondary dressing (see Case study 1, picture b). The green slough had been eliminated, the VAS pain score had reduced to 4 and the patient was now taking oral gabapentin for pain relief two to three times a day.

After 4 weeks of treatment, the wound measured 5.6 cm x 10.3 cm, the patient's visits to the specialist ulcer clinic had reduced to once weekly and pain medication was no longer required. The patient has now been discharged from the specialist clinic and is under the care of her practice nurse who she sees once a week where the wound is dressed with an adhesive silicone dressing as it nears complete healing.

**Case study 2**

This concerns an 86-year-old patient with a chronic venous leg ulcer. Her current ABPI is 0.84 and she had a wound on the dorsum of the foot measuring 3.8 cm x 2 cm that had been present for 3 years. The wound bed was covered with yellow slough, roughly 50%, and was producing large volumes of exudate. The dressing was changed on average twice a week and at initial assessment short-stretch compression bandages were being used but the wound still failed to progress as expected. It had previously been treated with



antimicrobial dressings containing silver, honey and PHMB. A small reduction in the amount of slough in the wound bed was noted but nothing significant. The use of a mechanical debridement pad was incorporated in the dressing regime, this removed some of the debris in the wound bed but overall the appearance remained the same. The patient was despondent about how long the wound was taking to heal. In addition, the dressings were so bulky that she was unable to wear her own footwear.

After 4 weeks of treatment with Zorflex alongside Kliniderm superabsorbent and two layers of Actico 2c compression worn for 7 days then changed in clinic, the wound reduced in size to 1.8 cm x 2.8 cm, approximately 40% of the slough had been removed, and the exudate level, which was originally high, was well controlled. The patient is continuing to use Zorflex, which is changed once weekly, and is now able to wear her own shoes.

'I feel like I have my life back now and I am more of a normal person. Who would think that something as being to wear my own shoes would be so significant'.

Mrs P