

# The use of the MIST System in an elderly burn patient

Vicky Edwards, Senior Burns Outreach Sister; Jacky Edwards, Burns Nurse Consultant; Burns Centre, Wythenshawe Hospital

## Introduction

With the increasing age profile of the population, it is becoming more common to see burn injuries in the elderly. These cohorts of patients are vulnerable to burns and their treatment can be challenging and complicated by chronic disease. More severe and deeper burns can be attributed to the elderly patients, due to thinner atrophic skin, a reduced microcirculation and reduced turnover rate of the epidermis and a lack of recuperative power in the healing process (Keck et al, 2009), these factors can lead to prolonged wound healing. There are no set criteria for defining chronic wounds, however Kane (2007) defines a chronic wound as a wound that has not resolved over a reasonable period of time no matter the cause, yet chronicity in burn wounds is often failed to be recognised. The essentials of burn care are debridement and infection control, as well as managing pain and anxiety. With full thickness or partial thickness wounds, there is often slough or necrotic tissue. It is essential that debridement of this tissue occurs, as the potential for infection is increased (Herndon, 2007) and subsequent wound healing delayed. The MIST Ultrasound Therapy System, has been shown to promote wound healing through wound cleansing and maintenance debridement by removal of yellow slough, fibrin, tissue exudate and bacteria.

The MIST Therapy System is a, non-thermal, low frequency, non-contact ultrasound; it delivers continuous ultrasonic energy to the wound site via an atomised saline solution (Waldrop and Serfass, 2008). Ultrasound delivers energy through mechanical vibrations (acoustic) in the form of sound waves at predetermined frequencies that are above detection by the human ear. The mechanism by which ultrasound is thought to work is by two processes. Cavitation which is the production and vibration of micron-sized bubbles, in the fluids within the tissues, and micro-streaming which is the movement of fluids along acoustic boundaries, these have a combined effect of altering cell membrane activity, which have a direct influence on wound healing (Kavos et al, 2007).

## Case Study

Mr A was a 79 year old gentleman, who had a history of strokes and atherosclerosis. He had sustained a full thickness contact burn injury to his right arm when he fell against a heater (see fig.1). The injury was surgically debrided and split skin grafted approximately 11 days post injury. He was discharged from hospital 7 days following surgery. The skin grafted area was managed with conventional dressings of silver sulfadiazine 1% and non-adherent dressing, however it was evident that approximately 20% of the graft had failed, these dressings were continued for a further 7 weeks with little progression in healing or reduction in wound size. Due to Mr A's hemiplegia on the left side, it was imperative that healing be achieved as quickly as possible on his right elbow, unfortunately further skin grafting was not deemed appropriate.

The decision was made to use the MIST Ultrasound Therapy System. Following staff training, Mr A had three times a week treatments of 3 minutes, this continued for 13 weeks in total. Conventional dressing of a Hydrogel was used between sessions, this was chosen as it can assist in the autolytic debridement by hydrating and lifting off slough and necrotic tissue (Wasiak et al, 2009). During every treatment the wound size was mapped, photographed and swabbed. Initially the MIST Therapy was administered in the clinic setting, but due to his poor mobility, the MIST unit was able to be used in the patients' own home.

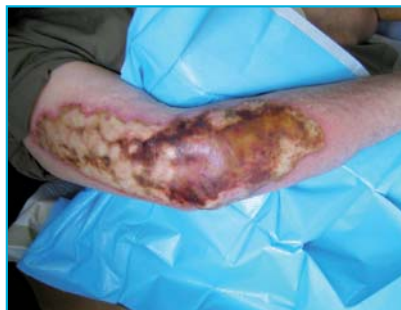

Fig 1: Initial Injury

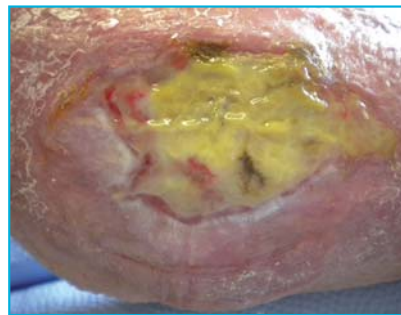


Fig 2: Start of MIST Therapy

## Results

Mr A reported no discomfort throughout the treatments, and said it was soothing. The pain score taken pre and post treatment were 0 out of 10 using a likert scale. The wound size initially was 5.5cm x 3.5cm = 11.2cm<sup>2</sup> (see fig.2), approximately six weeks into the treatment the wound size had reduced to 3.3cm x 2.5 cm = 4.7cm<sup>2</sup> (see fig.3), and when the wound size was reduced to 2.4cm x 1.9 cm = 2.6cm<sup>2</sup> (see fig.4) the treatment was discontinued. This showed a reduction in size of 59% at 6 weeks, and a total reduction at the end of the treatment by 77%. The wound continued to progress following discontinuation of the MIST Therapy, and when reviewing the photographs, the thickness of the slough was reduced and the wound size smaller (see fig.5). Burn patients are predisposed to infection because necrotic tissue is an excellent culture medium for micro-organisms. (Waldrop and Serfass, 2008), however despite having no systemic antibiotics or topical antimicrobials' throughout the treatment period, no clinical signs of infection were seen. The majority of the swabs either showed no growth or a mixed coagulase negative staphylococci, of no clinical significance. However there was one isolated swab towards the end of the treatment period that showed acinetobacter ursingii, again this was not clinically significant, and was not detected on any subsequent swabs.

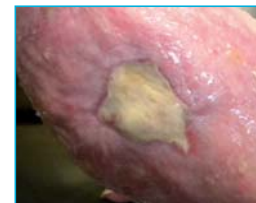

Fig 3: Week 6

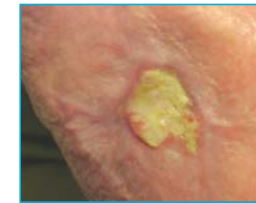


Fig 4: End of treatment

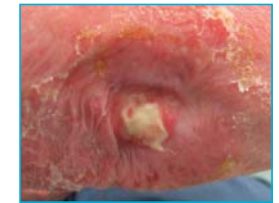


Fig 5: 4 weeks after MIST Therapy stopped

## Discussion

Whilst it is not possible to attribute the MIST Therapy solely to the reduction in wound size, as it could be argued that the wound size would have reduced with the use of a conventional dressing, there was a significant reduction in wound size and the overall appearance of the wound was improved. Wound healing is a complex and dynamic process of restoring cellular structures and tissue layers, non-healing or chronic wounds, are wounds that do not progress through the usual phases of healing. Percival and Bowler (2004) identified an adverse effect on wound healing caused by interactions of different microorganisms, they can become encased in an extracellular polysaccharide matrix (Myers, 2008) known as a biofilm. Therefore wound bed preparation is central to the healing process, removal of tissue that is colonised with substantial bioburden, which may include biofilms is an essential component of wound management. Kavros and Schenck (2007) report that there is cell wall destruction of bacteria with the use of MIST Therapy, and therefore reduction of biofilm and subsequently reducing infection. This is one explanation why despite no antibiotics or antimicrobials the patient did not exhibit any signs of clinical infection.

## Conclusions

From reviewing the literature and the authors' experience of the MIST Therapy System, it could be used as an adjunct to conventional burn care. However in order to establish the effectiveness of the MIST System in the management of burns a larger number of patients is required, however, early experiences demonstrate that there may be positives for using the MIST Therapy System in this particular patient cohort.

## References

1. Herndon DN (2007). Infection. Total Burn Care. (Third Edition). Galveston. Saunders Elsevier.
2. Kane DP. (2007) Chronic wound healing and chronic wound management. In: Chronic Wound Care: A Clinical Source Book for Health Professionals, 4th edition. Malvern, PA: HMP Communications; 11-23.
3. Kavos SJ, Miller JL, Hanna SW. (2007) Treatment of ischemic Wounds with Noncontact, Low-Frequency Ultrasound: The Mayo Clinic Experience, 2004-2006. Advances in Skin and Wound Care ;20:221-226.
4. Kavros SJ, Schenck EC. (2007) Use of Noncontact Low-Frequency Ultrasound in the Treatment of Chronic Foot and Leg Ulcerations. Journal of the American Podiatric Medical Association 97(2): 95-101.
5. Keck M, Lumenta DB, Andel H, Kamolz LP.(2009) Burn treatment in the elderly. Burns 35:1071-1079.
6. Myers BA (2008) Wound Management: Principles and Practice. Second edition. Pearson Education, New Jersey NJ.
7. Percival SL, Bowler PG. (2004) Biofilms and their potential role in wound healing. Wounds, 16, 7: 234-240.
8. Waldrop K, Serfass A. (2008) Clinical Effectiveness of Noncontact, Low-Frequency, Nonthermal Ultrasound in Burn Care. OstomyWound Management 54(6):66-69.
9. Wasiak J, Cleland H, Campbell F (2009) Dressings for superficial and partial thickness burns. The Cochrane Collaboration. Wiley Publishers